

# implants

international magazine of oral implantology

3<sup>2009</sup>

**\_case report**

Bone quality, quantity and metabolism  
in terms of dental implantation

**\_case reprt**

Precautions for using zirconia implant  
abutments

**\_worldwide events**

5<sup>th</sup> Arab German Implantology Meeting  
DGZI in Damascus

# Resorption mechanism of an injectable calcium phosphate bone regeneration cement – Radiographic and histological monitoring

author\_ Sérgio Alexandre Gehrke, Brazil

## \_Introduction

Calcium phosphate cements have been extensively studied since the 80's for their application as bone substitutes in various indications, mainly in the orthopaedic and odontology fields. They are well suited for osseous repair and reconstruction, because they proved to be biocompatible, osteoconductive and resorbable. However, their main interest lies in the fact that they are easy to apply in situ, can be shaped, and finally harden, thus providing a stability which is beneficial to the reconstruction site and the whole bone formation process.

Calcium phosphate bone cements are often known as products exhibiting very slow resorption. It was even shown that a particular apatite cement presents extremely limited resorption and osteoconduction after 12 months in a sheep model for craniofacial repair (Zins 2008). This slow resorption characterizing some calcium phosphate cements is partly due to the absence of macroporosity in the hardened cement. Nevertheless, it is important, when dealing with bone cements, to look into their composition once hardened. Most of the calcium phosphate bone ce-

ments consist of apatite after setting (hydroxyapatite or carbonated apatite), which is the most stable phase in vivo. Another type of calcium phosphate cement is the brushite cement. Brushite is the less stable calcium phosphate compound in vivo, and the only one to be soluble in blood serum. This means that the chemical nature of brushite cements (quickly resorbed) theoretically compensates their lack of macroporosity (slowing down the resorption rate). This difference in resorption process between apatite and brushite cement was clearly evidenced by Apelt and co-authors in a sheep model study (Apelt 2003).

As far as we know, most of the brushite cements are still in the development phase and only two of them are already on the market: one for orthopedic surgery (Jectos®, Kasios®, France), and one for dental applications. The latter is called PD VitalOs Cement® (Produits Dentaires SA, Switzerland). It has been specifically designed for dental surgery and offers the following practical advantages:

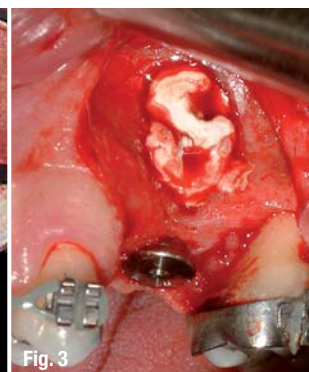
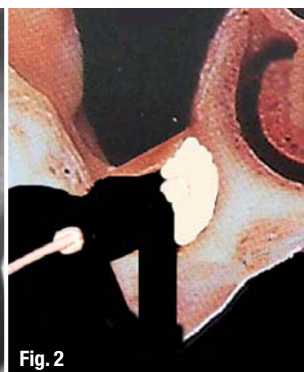
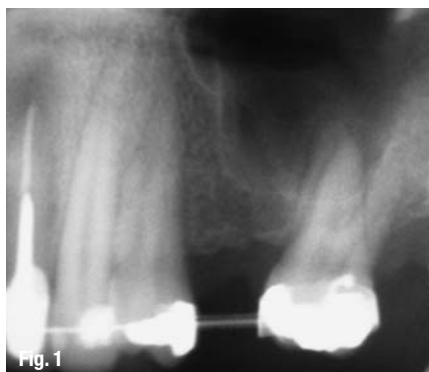It can be easily injected in cavities offering limited access;

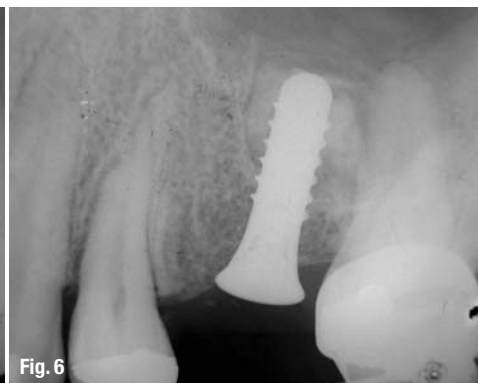
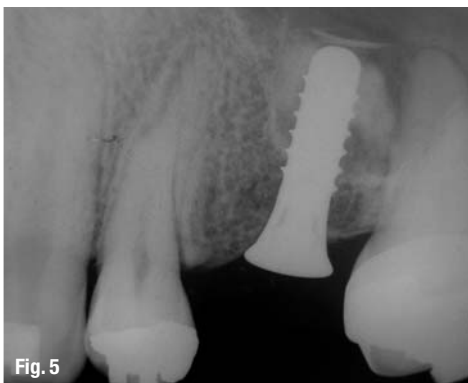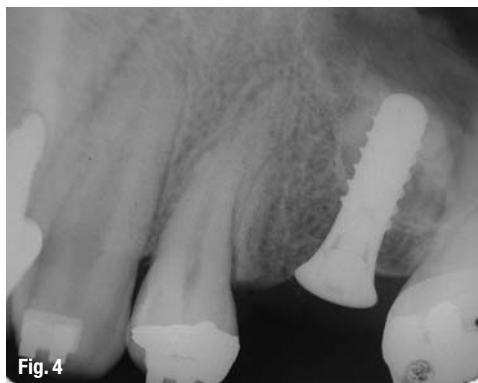It is ready to inject: no preparation of the cement is needed during surgery;

**Fig. 1** Pre-operative radiograph (case I).

**Fig. 2** Illustration of the installation of the first cement portion, against the inner wall of the sinus cavity.

**Fig. 3** Sinus cavity completely filled with VitalOs, after installation of the implant.





**Fig. 4–7\_** Radiographs of case I at 30, 60, 120 and 180 days after surgery.

It anchors well onto the bone and implant surfaces, providing suitable stability between bone and implant;

It hardens, acquiring its own mechanical stability;

It shows adequate radiopacity allowing radiographic monitoring of its resorption.

This paper aims at understanding the resorption process of PD VitalOs Cement and simultaneous bone neoformation, when the cement is used in osseous defects around implants. Two cases were selected to show how the cement degradation can be followed up through radiographic monitoring. To illustrate and provide explanation to some of the findings, results of an *in vivo* study run by the author are presented as well. In this study, the resorption of various bone substitutes and simultaneous bone neoformation were followed up with the help of fluorescent bone markers.

### Case I

The first case is a 30-year old male patient, in good health condition, non-smoker, presenting with absence of tooth 25, with pneumatization of the maxillary sinus.

This situation required the regeneration of osseous tissue for the installation of a dental implant. As there was enough bone structure to provide the implant with primary stability, a sinus floor elevation was proposed, with installation of the implant in the same surgery.

### *Surgical protocol*

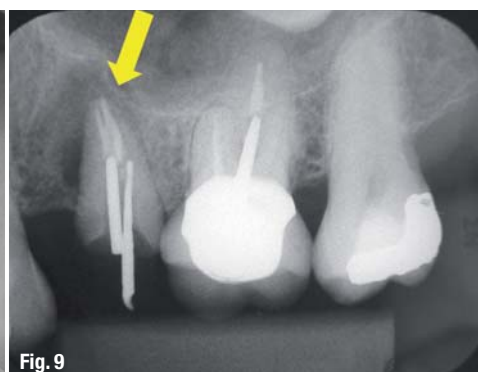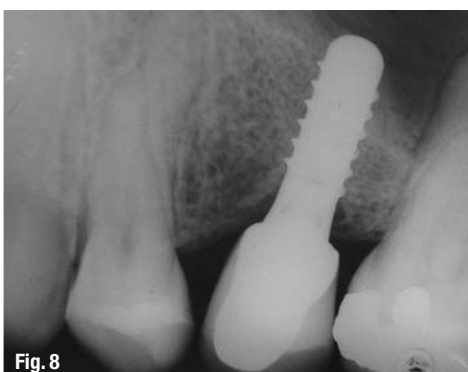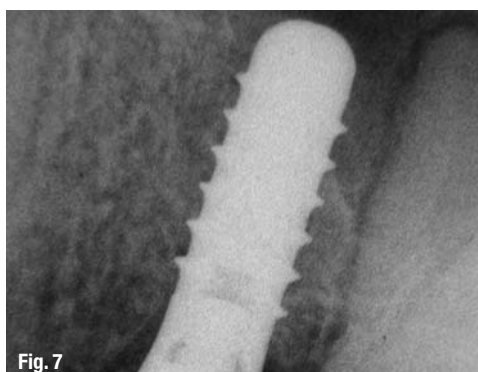
After administration of a local anesthetic, a lateral access to the sinus cavity was performed through a lateral window. Then, the sinus membrane was carefully lifted up to the desired height. The drilling of the site was performed according to the recommendations of the manufacturer. During this phase, particular attention was paid to avoid perforating the membrane with the drills. A gaze humidified with a vasoconstrictor solution was placed into the sinus cavity for 5 minutes to control the bleeding as efficiently as possible. Indeed, blood flow must be avoided during injection of the VitalOs cement in order to allow contact between cement and bone and anchoring of VitalOs onto the sinus wall. Then, the cement was injected into the sinus to fill the space between the inner (nasal) wall of the cavity and the space prepared for the installation of the implant (fig. 2). Once the cement was hard, the implant was installed as planned. Finally, the rest of the cavity was filled up with VitalOs up to the edges of the lateral window, without using a membrane. Indeed, the use of a membrane is not necessary with VitalOs, since the product acts itself also as a barrier.

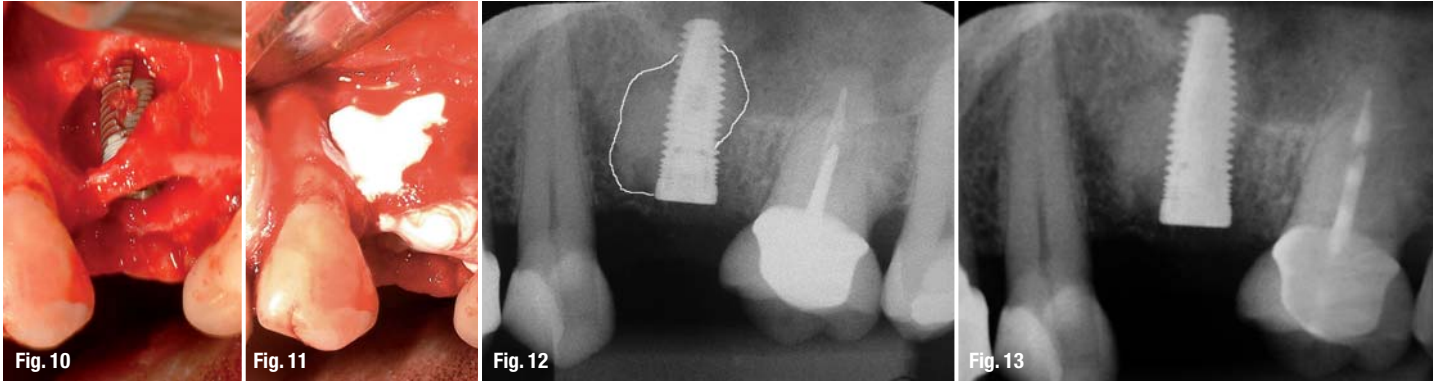
### *Radiographic control*

Thanks to the adequate radiopacity of the cement, it is easy to perform a radiographic follow-up and analysis of the resorption and new bone growth. Radiographs were therefore taken at 30, 60, 120 and 180 days after implant installation (figs. 4–7), as well as 12 months (fig. 8) after installation of the restora-

**Fig. 8\_** Radiograph of case I taken 12 months after loading.

**Fig. 9\_** Pre-operative radiograph (case II).





**Fig. 10, 11**\_ Implant installation and filling with PD VitalOs Cement.

**Fig. 12–15**\_ Radiographs of case II at 30, 60, 120 and 180 days after surgery.

**Fig. 16**\_ Radiograph of case II taken 12 months after loading.

tion, to follow-up the behavior of the new bone after loading of the implant.

**\_Case II**

The second case is a 40-year old female patient in good health condition, non-smoking, presenting with a fracture of tooth 14 and presence of a large radicular cyst (fig. 9) requiring removal of the root. The site presented a very large loss of bony structure, with fenestration of the buccal side of the socket wall. Therefore, the implant could only be stabilized in the inferior wall of the sinus cavity with the use of Summers' osteotomes.

*Surgical protocol*

After administration of a local anesthetic, the access to the remaining portion of the root was performed and the root was carefully extracted, paying attention to preserve as much as possible the remaining osseous tissue. Thorough curettage of the apical portion was made to remove completely the cyst and the soft tissues. The implantation bed was then prepared with the osteotomes in order to gain sufficient stability. The implant was installed (fig. 10) and the large bony defect was filled with the injectable VitalOs cement (fig. 11). At this stage it is important to control bleeding during and after injection until the cement is set. This is done with the help of a suction canula in the vicinity of the hardening cement. Although the cement itself promotes to a certain extent hemostasis in the site where it is injected,

the bleeding occurring in the neighboring soft tissues must be controlled during the 5 minutes necessary for the cement to set.

*Radiographic control*

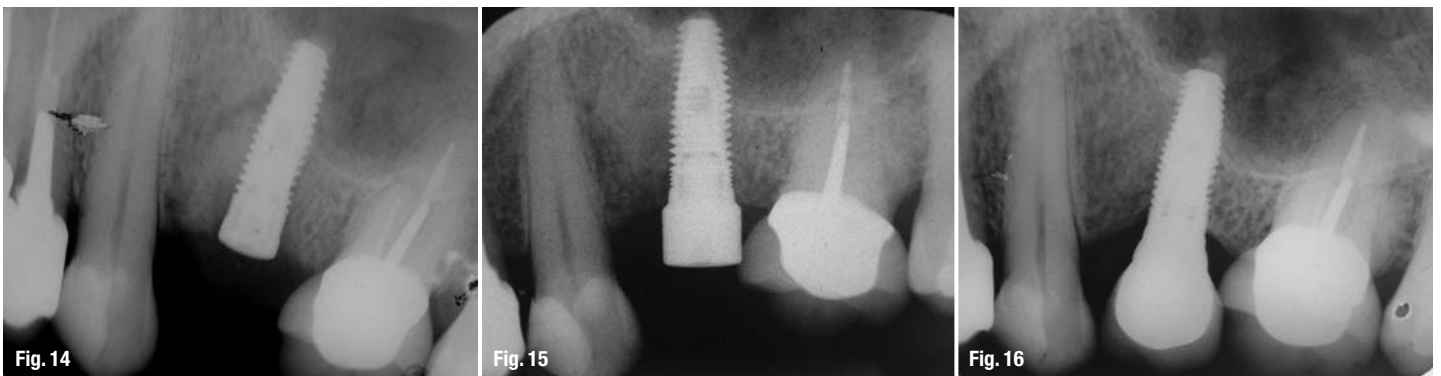
The control performed followed the same schedule described for the case I, i.e. radiographs were taken at 30, 60, 120 and 180 days after implant installation (figs. 12-15), as well as 12 months (fig. 16) after installation of the restoration.


**\_Histological study in animal model**

It is quite interesting to link the radiographic control of the presented cases with histological results obtained from a study where various bone substitutes were implanted in rabbit tibiae. The bone neoformation in the augmented cylindrical defects (4 mm diameter) was followed up by injecting polyfluorochromic bone markers during the first weeks following surgery: alizarin after 14 and 21 days, calcein after 28 and 35 days, tetracycline after 42 and 49 days. The animals were sacrificed at day 56. The investigated products were two granular bone substitutes (Geistlich Bio-Oss® and Straumann® Bone Ceramic) and a bone cement (PD VitalOs Cement®).

**\_Results**

The radiographs taken 30 days after surgery show the beginning of resorption at the periphery of the Vi-





**Fig. 17–19** Fluorescence histologies of sites filled with VitalOs, Bio-Oss and Bone Ceramic respectively.

talOs cement. This process progresses towards the center of the cement mass. In the sinus lift case, the progress also takes place from the coronal towards the apical region around the implant (yellow arrows on figure 4). Across the different times of analysis it is possible to see that the material is gradually being replaced and the osseous tissue is being formed, apparently without incorporation of cement particles. At the end of the neoformation process, the newly formed bone displays radiographic characteristics which are similar to those of the native surrounding bone. This is also confirmed after 12 months of loading, where the bone around the implant has not resorbed, indicating a good preservation of the new osseous volume around the implant.

The results of the histological study show that the injectable brushite cement resorbs much more uniformly and rapidly than the granular materials (figs. 17-19). It is also possible to state that the ossification process in the defects filled with VitalOs starts in the first weeks after augmentation: intensive brick-red areas due to alizarin indicate bone deposition between the second and the fourth week, and green areas due to calcein reveal the osteogenesis activity after 4-6 weeks. The coloration of the osteogenesis areas is more intense at every follow-up stage in the defects filled with the cement than in those filled with granular materials. This shows the maturity of the bone in the sites grafted with the brushite cement. Moreover, the organization of this newly formed bone tissue presents a structure which is more suitable for subsequent implant installation, i.e. a more organized and lamellar bone, with presence of osteons (yellow arrows, fig. 17).

New bone formation is also seen in the defects grafted with granules. However, the bone deposition is stronger in the calcein phase (green fluorescence, see fig. 18-19) than in the alizarin one (red), which indicates a delayed bone formation, starting 4 weeks after surgery. The fluorescence of the new bone tissue is weaker than in the sites filled with PD VitalOs Cement, which is a sign for lower maturity of the new bone tissue.

## Discussion

The radiographic follow-up of the augmented sites shows clearly that the resorption takes place from the cement periphery towards its center until it is completely substituted by newly formed bone.

Brushite cements are known to resorb from their outer surface in contact with bone, towards the inner core of the injected mass. The resorption of brushite takes place through a combination of dissolution and cell-mediated processes. The whole process happens at the bone-cement interface, called resorption front (Theiss 2005, Lu 2002). This resorption front can always be easily located on radiographs and allows accurate determination of the moment when the cement is completely resorbed and replaced by bone. An earlier publication of the same author in the first implants edition of this year showed that the newly formed tissue does not contain any cement remnants and displays a lamellar, well organized structure (Gehrke 2009).

As we could observe in the radiographic sequences presented here, the injectable VitalOs cement presents a good radiopacity during the whole duration of the resorption process. The cement is easily located on the radiographs because it produces white homogeneous areas that distinguish clearly from the surrounding bone structure. This difference is easily recognizable until the very end of the resorption process. The radiopacity of this cement was shown to be equivalent to that of cortical bone (Pittet 2002). These features definitely facilitate the follow-up of its resorption and help the professional determining when the implant can be loaded.

Why is it so important to determine accurately the right time for loading the implant? There are several reasons for this. First, to make sure that the structure surrounding the implant is able to withstand the stresses applied through the crown-implant system. The residual bone used as bed for implantation provides the initial stability to the implant, but in most cases its quantity and structure are not sufficient to support the stresses applied on the implant once it is in function. The presence of newly

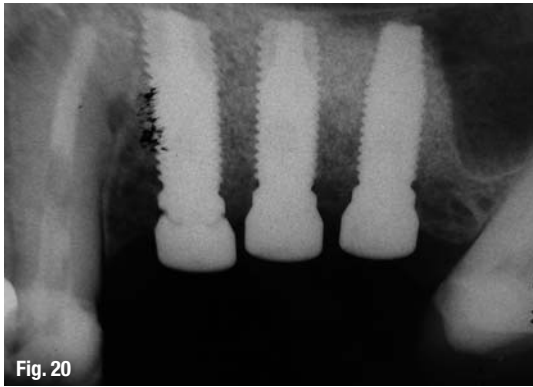

Fig. 20

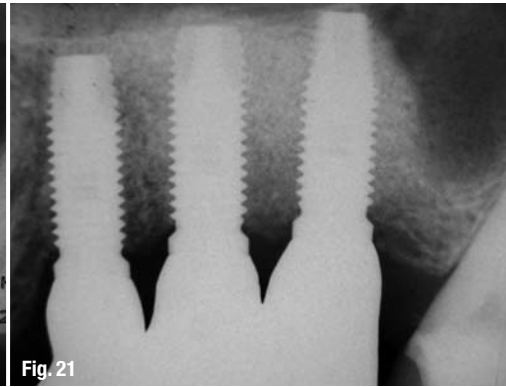


Fig. 21

**Fig. 20, 21** Radiographs of a case augmented with Bone Ceramic: 180 days after surgery and 1 year after crown installation, respectively.

formed bone around the implant is therefore required to provide the required mechanical stability.

Now, the time necessary for substitution of the graft material by newly formed bone may vary from one case to another. In a maxillary sinus as in case I, the cement generally resorbs completely in 6 months. Nevertheless, this period can be longer in older patients or in patients presenting metabolic disturbances. In these cases it is necessary to wait longer before starting the prosthetic phase.

In addition to that, this time period also depends on the volume or thickness of material applied: the larger it is, the longer it takes to resorb and be replaced by new bone tissue. These various factors influencing the resorption time of the graft material make it impossible to predict accurately when the augmented bone site will be ready to withstand the load applied onto the implant.

For all these reasons, the ease of location of the grafting material on radiographs is of great advantage: it allows following each patient individually to estimate the level of new bone reconstruction. This is important since this process is very much patient-dependent and should be assessed individually in order to choose the right time for installing the restoration. Finally, it is also the predictability of the treatment success which is increased through accurate radiographic monitoring.

The radiographic monitoring is more difficult to achieve with granular materials because their appearance on radiographs is closer to that of bone and the grafted area becomes eventually a mix of granules and bony tissue. To emphasize this, figures 20 and 21 show radiographs of sites augmented with granular materials (Bone Ceramic), 180 days after augmentation and one year after crown installation, respectively. It can be seen that the newly formed bone is not as well defined as in the cases filled with the brushite cement (fig. 15). The resorption mechanism of granular materials is also accompanied by new bone formation, but this takes place between the granules, most of them remaining eventually embedded in the new bone structure.

On the histologies, the bone markers showed that the substitution of the cement by bone starts during

the first weeks after implantation. The bone tissue eventually obtained after 8 weeks in the model is well organized, displaying a much more suitable structure than the bone growing in the defects filled with granular materials. The results obtained here are in accordance with results from literature showing that brushite cements exhibit fast resorption (Theiss 2005, Lu 2002), despite their lack of macroporosity. This good capacity of resorption and substitution by osseous tissue confirms the osteogenic potential of PD VitalOs Cement.

## Conclusion

This paper evidences and discusses the different resorption kinetics and mechanisms occurring between a brushite calcium phosphate cement, VitalOs Cement, and granular bone substitutes. We showed that the good radiopacity of VitalOs allows more precise and secure monitoring of the resorption and substitution of the cement by new bone tissue. The neoformation kinetics is also patient-dependent and the ease to monitor radiographically the resorption process adds reliability to the overall treatment.

In summary, it was shown here that:

The radiopacity of the cement allows easy and reliable monitoring of the resorption process;

Osteogenesis starts earlier in the cement than in the granular substitutes presented here;

The bone neoformation is more intensive in contact with VitalOs than with granular products;

The cement is fully resorbed and its substitution by new bone tissue requires less time than with the granular substitutes. \_

## \_contact

## implants

### Dr Sérgio Alexandre Gehrke

BioFace Institut

Dr. Bozano, 571

Santa Maria – RS, Brazil

E-mail: Sergio.gehrke@terra.com.br